Case of the month_ February 2013

A 47-year old lady with progressive seizures and expressive dysphasia

Andreas Demetriades, Ranj Bhangoo, Richard Gullan (Neurosurgery),&,
Samir Al-Hyassat , Safa Al-Sarraj (Neuropathology)
KING'S COLLEGE HOSPITAL, LONDON, UK
(correspondence: andreas.demetriades@gmail.com)

A 47 year old right handed lady presented with two generalised tonic clonic seizures. She had no past medical history and a normal neurological examination. Neuroimaging was obtained:

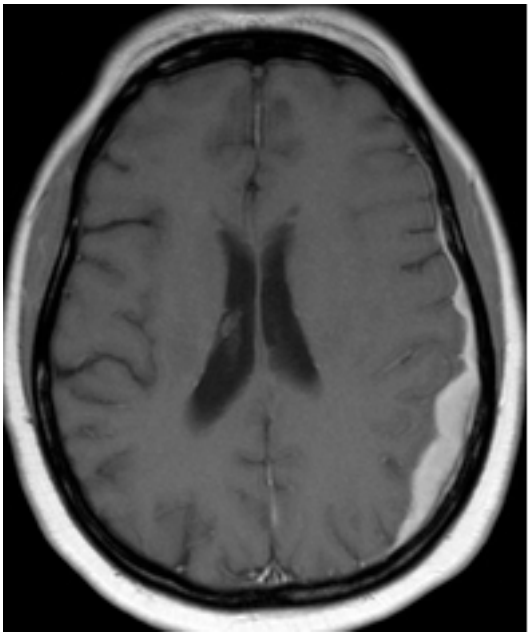

Question 1: What is your provisional diagnosis based on the MRI examination?

a) **Meningioma-en-plaque**
b) **Meningiomatosis**
c) **Leptomeningeal metastasis**
d) **Empyema**
e) **Other:**

Question 2: How would you proceed?

a) **Treat the seizures with anti-epileptic drugs (AED) and continue with radiological surveillance**
b) **Commence AED and arrange a biopsy**
c) **Commence AED and arrange a surgical resection**
d) **Radiation therapy**
e) **Stereotactic radiosurgery**
f) **Other:**

She was commenced on AED. Although surgery was discussed, she was not keen on it. Pharmacological management with radiological surveillance was recommended.

She had good seizure control for a year, however it became obvious that she had gradually worsened symptomatically. Specifically she had problems with expressive dysphasia. Her family were also expressing concerns of some cognitive decline. Up-to-date scans showed the same extensive lesion, which was presumed to be a meningioma (benign tumour) covering a large part of the left hemisphere of her brain.
This was deemed to have grown further since the previous visit.

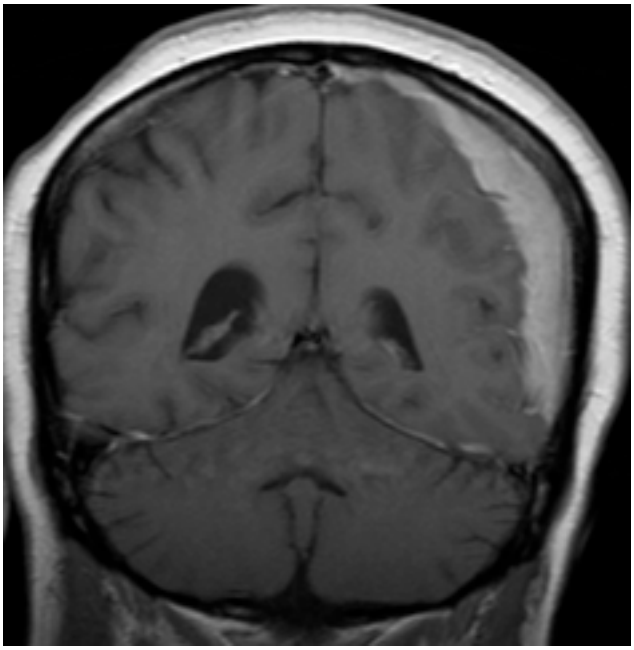

Question 3: Given the symptomatic and radiological progression, how would you proceed now?

a) **Treat the seizures with anti-epileptic drugs (AED) and continue with radiological surveillance**
b) **Commence AED and arrange a biopsy**
c) **Commence AED and arrange a surgical resection**
d) **Radiation therapy**
e) **Stereotactic radiosurgery**
f) **Other:**

After discussion at the Neuro-Oncology Multi-disciplinary Meeting (Tumour Board) she was offered surgery and thereafter admitted electively for an operation.
During this operation she had an image-guided craniotomy and de-bulking of the left-sided tumour. Unfortunately this operation was complicated. Soon after dural opening, she suffered an on-table cardiac arrest with profound hypotension and bradycardia, as well as profuse bleeding.

Question 4: How would you proceed?

a) **Resuscitate, stabilise, and continue the operation.**
b) **Resuscitate, stabilise, close, and reschedule the operation.**
c) **Resuscitate, stabilise, close, and consider not re-operating.**

The bulk of the tumour was rapidly removed and haemostasis achieved. In the interests of saving her life the operation was abandoned, so that she could be stabilised in Neuro-

Intensive Care. She had a stormy post-operative course during which time she suffered from further epileptic seizures. After eventually being weaned off the ventilator she had signs of a stroke. Furthermore, she developed a wound infection and needed a second operation and removal of the bone flap as well as warranted debridement.

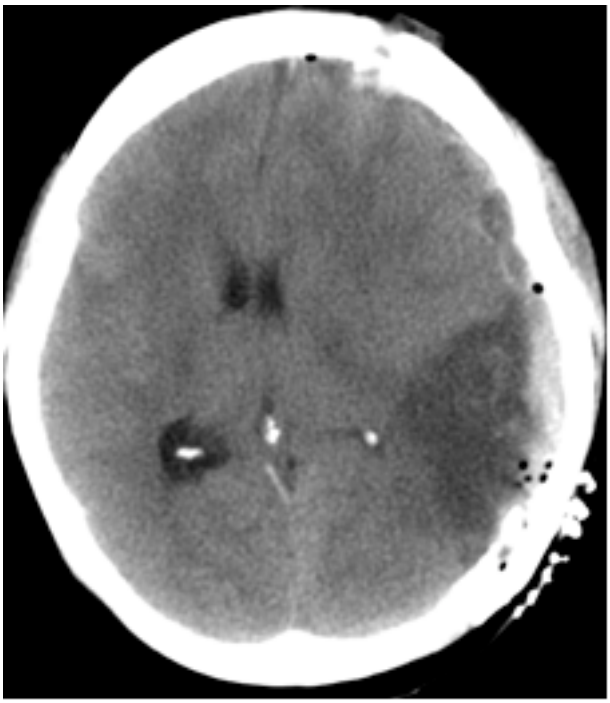

Question 6: What next?

a) **no further surgery**
b) **no further surgery, but radiotherapy**
c) **reschedule complete resection when possible**

She slowly made a significant amount of progress receiving input from Occupational Therapy, Physiotherapy, Speech and Language Therapy and the Nutrition Team. Her seizures came under control. With ongoing inpatient rehabilitation, she was able to be transferred to a full-time Rehabilitation Centre after having spent three months as an inpatient.

Histopathology:

The histopathological examination revealed a thickened dura with fibrous connective tissue and a mixed mononuclear inflammatory infiltrate composed of lymphocytes, plasma cells, and large histiocytes. The lymphocytic infiltrate was diffuse, but focally dense. There were areas of a follicular-like arrangement of lymphocytes but with large numbers of plasma cells. The plasma cells displayed a prominent perivascular pattern, but also appeared to be permeating collagen fibres.

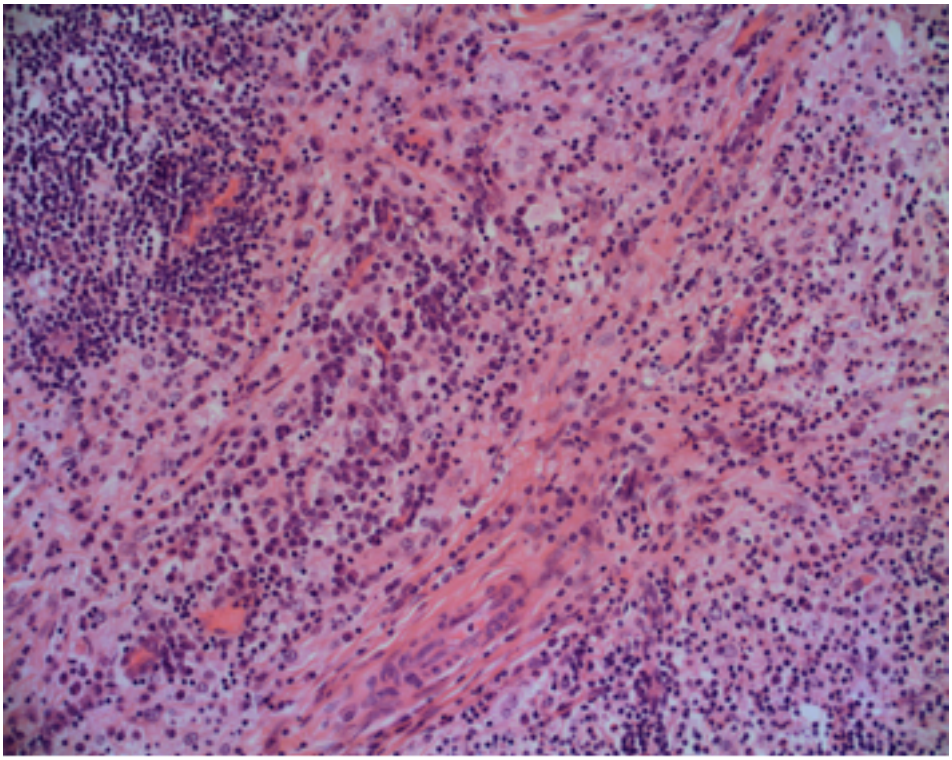

In several areas there was a background of larger cells with a pale granular eosinophilic cytoplasm, some exhibiting emperiopolesis with intracytoplasmic lymphocytes. Immunohistochemistry revealed the larger cells to be positive for S100. There were large numbers of macrophages within the specimen including occasional larger cells as seen on CD68. The CD45 confirmed large numbers of lymphocytes and these were a mixture of B (CD20 and CD79a) and T cells. There was positivity for both kappa and lambda favouring a polyclonal B cell component. The EMA highlighted the plasma cells but there was only mild staining in the mesenchymal background component. There was no evidence of meningothelial proliferation. The CD34 was negative. The stains for bacteria, fungi and acid-alcohol fast bacilli are negative.

Question 7: The diagnosis is:

DISCUSSION:

The differential diagnosis included lymphoplasmacyte-rich meningioma; MALT lymphoma; an infective process; plasma cell granuloma (inflammatory pseudo-tumour); and Rosai-Dorfman disease.

- Whilst the entity of a lymphoplasmacyte rich meningioma exists and is in the differential diagnosis, there was no evidence for meningothelial proliferation.
- MALT lymphomas have been described at this site but the lymphocytes were a mixture of B and T cells, and the CD20 positive lymphoplasmacytic component here appeared polyclonal.
- An infective process is possible but less likely taking in consideration the negative special stains and the absence of clinical signs and symptoms of infection. There are some inflammatory lesions such as plasma cell granuloma, which remain strong possibilities.

Overall, the findings favoured the diagnosis of an inflammatory process, strongly favouring **Rosai-Dorfman disease.**

Rosai-Dorfman is a non-neoplastic lymphoplasmacytic proliferative disease. It can be intranodal and extranodal. It is characterised by massive painless cervical lymphadenopathy, fever and weight loss, in over 90% of cases. Interestingly, however, none of these were present in our patient. Extranodal disease is present in about 30% of cases and may involve the upper respiratory tract, skin, eyes and orbit, testes, and salivary glands. This extremely rare inflammatory lesion can release histamine. It is believed that this may have had a role to play with this patient's on-table cardiac arrest. Aetiology remains unclear, though some links point to a non-specific immune dysfunction with viral involvement.

Central nervous system manifestations are extremely rare; intracranial involvement usually mimics a meningioma both clinically and radiologically, as a duraly based solitary lesion. Several intracranial locations have been reported, including convexity, cavernous sinus, clivus, suprasellar region; but also parenchyma, ventricular system, and cerebellum. It may also present as pachymeningitis. Symptoms may include headaches and seizures; dysphasia; cranial nerve deficits; visual deterioration; paresis; endocrinopathy. Treatment regimes have included biopsy, debulking, and resection. Adjuvant treatment has included chemotherapy, radiotherapy, radiosurgery, and steroid administration. Prognosis is benign especially in the absence of intranodal disease. Recurrence can be as high as 15% at 10 years.

Though rare, Rosai-Dorfman disease should be considered in the differential diagnosis of 'unusual' durally-based lesions such as 'presumed' meningiomas.